

## Report

**A multicenter, randomized, split-face clinical trial evaluating the efficacy and safety of chromophore gel-assisted blue light phototherapy for the treatment of acne**

Christina Antoniou<sup>1</sup>, MD, Clio Dessinioti<sup>1</sup>, MD, Dimitrios Sotiriadis<sup>2</sup>, MD, Konstantinos Kalokasidis<sup>2</sup>, MD, George Kontochristopoulos<sup>3</sup>, MD, Athanasios Petridis<sup>4</sup>, MD, Dimitrios Rigopoulos<sup>5</sup>, MD, Denis Vezina<sup>6</sup>, PhD, and Andreas Nikolis<sup>7,8</sup>, MD, MSc, FRCSC

<sup>1</sup>1st Department of Dermatology, University of Athens, Andreas Sygros Hospital, Athens, <sup>2</sup>Department of Dermatology, Aristotle University of Thessaloniki Medical School, Papageorgiou General Hospital, Thessaloniki, <sup>3</sup>2nd Department of Dermatology, <sup>4</sup>3rd Department of Dermatology, Andreas Sygros Hospital, <sup>5</sup>University of Athens, Attikon University General Hospital of Athens, Athens, Greece, <sup>6</sup>KLOX Technologies Inc., Laval, <sup>7</sup>Division of Plastic Surgery, University of Montreal, and <sup>8</sup>Victoria Park Research Centre, Plastic Surgery Section, Montreal, Canada

**Correspondence**

Dr. Andreas Nikolis, MD, MSc, FRCSC  
Victoria Park Research Centre  
376 Victoria, Suite 400  
Westmount, QC, Canada  
E-mail: anikolis@vicpark.com

**Conflicts of interest:** DV is employee of KLOX Technologies Inc. and AN is an advisor to Klox Technologies Inc.

doi: 10.1111/ijd.13349

**Abstract**

**Background** Although a variety of laser/light-based devices have been reported to be effective for the treatment of acne, long-term data on efficacy and safety in the management of moderate and severe inflammatory acne is lacking. The objective of this 12-week clinical trial was to evaluate the efficacy and safety of the KLOX BioPhotonic System, a LED blue light device using specific photo-converter chromophores, in the treatment of moderate to severe acne vulgaris.

**Methods** One patient hemiface was randomly selected to receive 6 weeks of treatment (twice weekly) with the LED light and the photo-converter chromophores whereas the contralateral hemiface was not treated with the BioPhotonic System. All patients were provided with a skin cleanser and a non-comedogenic cream with ultraviolet protection to be used on the entire face during the treatment period. Following completion of the 6-week treatment period, the patient was followed for an additional 6 weeks. Efficacy was assessed through changes in acne severity using the Investigator's Global Assessment (IGA) scale and inflammatory acne lesion counts, both evaluated against baseline at weeks 6 and 12. Safety was assessed through physical exam, vital signs, laboratory evaluations, and physician and patient reporting of adverse events.

**Results** A reduction of at least two grades in IGA scale severity was demonstrated in 51.7% of patients at week 12. Furthermore, at week 12, subjects with a baseline IGA grade of 3 (moderate) demonstrated a success rate (2 or greater grade drop) of 45.3% whereas patients with a baseline IGA grade of 4 (severe) demonstrated a success rate of 61.1%. Acne inflammatory lesion counts confirmed these results, with a reduction of at least 40% of lesions in 81.6% of treated hemifaces after 12 weeks. Treatment was considered as safe and well tolerated, with no serious adverse event and no patient discontinuation from the study from any adverse event. Patients' quality of life was also improved with a decrease of pain linked to acne after the 6-week treatment period.

**Conclusions** The BioPhotonic System comprised of LED blue-light phototherapy and photo-converter chromophores was found to be efficacious and safe, with a sustained clinical response at 12 weeks for the management of moderate to severe facial inflammatory acne.

**Introduction**

Acne vulgaris is estimated to affect 9.4% of the global population, making it the eighth most prevalent disease worldwide,<sup>1</sup> and the most common skin disease affecting nearly all adolescents and up to 64% of young adults.<sup>2</sup> Acne has been recently redefined as a chronic inflammatory skin disorder with a significant psychological and

social negative impact on patients.<sup>2</sup> Optical treatments including laser and light-based therapies (photodynamic therapy [PDT], light-emitting diode [LED], and intense pulsed light) have gained increasing interest over the last years as acne treatments,<sup>3,4</sup> due to the limitations associated with standard established acne therapies: the teratogenicity of isotretinoin; contraindications associated with hormonal agents; and worldwide emergence of antibiotic-

resistant *Propionibacterium acnes* with oral and topical antibiotics.<sup>3,5</sup>

The rationale of using visible light for acne therapy is to excite the endogenous porphyrins produced by *P. acnes* in the skin (with highest peak of light absorption at 400–420 nm, Soret band), resulting in an endogenous photodynamic reaction with singlet oxygen production that decreases the size of sebaceous glands and kills bacteria.<sup>2,6</sup> Light phototherapy for acne presents many advantages as it is a non-invasive, in-office, light-based method with no systemic side effects. Light therapy is an attractive approach for acne, as visible light does not increase antibiotic bacterial resistance, it may be repeated in case of acne relapses, and it may increase compliance, as patients do not have to adhere to complex application regimens or oral drug intake. Furthermore, it does not cause intense problematic topical side effects as those associated with PDT, namely skin erythema, edema, pain, burning, pustules, crusting, and exfoliation.<sup>7–9</sup>

However, the most recently published guidelines and consensus recommendations for the treatment of acne state that light therapy cannot be recommended for moderate to severe inflammatory acne due to the lack of well-designed randomized controlled studies evaluating light therapy for acne.<sup>2,7</sup>

We conducted a multicenter, randomized, split-face 12-week study to assess the effectiveness and safety of chromophore-assisted blue light phototherapy for moderate and severe facial inflammatory acne vulgaris.

## Patients and Methods

Between March 2012 and December 2012, a multicenter, prospective, randomized, open-label, split-face clinical trial (CL-K1005-P001) was conducted to assess the efficacy and safety of the KLOX BioPhotonic system (class 2a medical device; KLOX Technologies Inc., Laval, Canada) comprised of a topical photoconverter chromophore gel (KLGA0105-01) and a blue light-emitting (415/446 nm, with peak wavelength at 446 nm) multi-LED device (KLOX THERA™ lamp) for the treatment of moderate to severe facial acne vulgaris. Preclinical data indicated that the multi-LED light passes through the gel and is diffracted into different wavelengths with variable skin penetration properties and activities. Through the activation of the gel chromophores, fluorescence is also generated via the production of photons (KLOX Technologies, Data on file). The power density of the LED light was between 110 and 150 mW/cm<sup>2</sup> at a distance of 5 cm from the light source with a radiant fluence (or dose) during a single treatment for 5 minutes of 33–45 J/cm<sup>2</sup>.

Five hospital-based Dermatology University Departments in Greece participated in the study (four in Athens and one in Thessaloniki). The study was performed in accordance with the

Declaration of Helsinki and the International Conference of Harmonization (ICH) Guidelines for Clinical Practice. Study approval was given by the Greek Competent Authority and the National Ethics Board (Clinicaltrials.gov registration number: NCT01584674). All participants gave their written informed consent before any study procedures, and for minors a parent or guardian also signed the informed consent form. A separate consent was signed by patients for the publication of facial photographs.

Inclusion criteria included age 16–30 years, Fitzpatrick skin types I–IV, history of active acne vulgaris for at least 6 months, moderate to severe acne as defined by the Investigator's Global Assessment (IGA) scale<sup>10</sup> (Table 1), and lesion count: moderate acne defined as IGA grade 3 and 20–40 inflammatory lesions (papules or pustules) and ≤1 inflammatory nodule; severe acne defined as IGA grade 4 with more than 40 inflammatory lesions, ≤2 inflammatory nodules and/or the presence of severe erythema and inflammatory scarring type lesions. It was required that included patients had similar acne on both sides of the face as defined by the same IGA grade and similar acne lesion counts on both sides of their face. Enrolled female participants had a negative pregnancy test (serum β-human chorionic gonadotropin), and participants were willing to practice birth control during their participation in the study.

Exclusion criteria included active skin or systemic infection, any aesthetic facial procedure including laser therapy and tissue/dermal injectables within the last 6 months, light-based therapy in the last 4 months, use of hormonal oral contraception, any facial dermatological conditions that might interfere with clinical assessments performed in the present study, immunosuppression and/or cortisone therapy in the 4 months preceding the present study, bleeding diathesis, medications or supplements affecting coagulation, oral isotretinoin in the last 6 months, pregnancy or breastfeeding, history of facial nerve palsy or marked facial asymmetry, history of neuromuscular disorder, or previous facial surgery that altered subcutaneous tissues (e.g., rhytidectomy).

**Table 1** Investigator's global assessment grading for acne vulgaris

Grade	Description
0	Clear skin with no inflammatory or non-inflammatory lesions
1	Almost clear, with no more than one small inflammatory lesion
2	Mild severity; greater than grade 1; with no more than a few inflammatory lesions (papules/pustules only, no nodular lesions)
3	Moderate severity; greater than grade 2; may have some inflammatory lesions, but no more than one small nodular lesion
4	Severe; greater than grade 3; up to many inflammatory lesions, but no more than a few nodular lesions

The half of the face to be treated was selected after blinded randomization by a computer-generated list. The study gel was applied on the treated half of the face (hemiface) in a 2 mm thick layer, and this hemiface was immediately illuminated with the multi-LED lamp for 5 minutes at a 5 cm distance from the light source. After the illumination, the gel was removed and rinsed off. The other half of the face was left untreated as the control. Treatment sessions were carried out biweekly for 6 weeks, and then patients visited the site every 2 weeks without treatment for another 6 weeks for follow-up. All patients were provided with a skin cleanser (Cetaphil, GALDERMA, Lausanne, Switzerland) and a non-comedogenic cream with ultraviolet protection (Cetaphil cream, SPF 50, GALDERMA, Lausanne, Switzerland) to apply on their whole face, for daily cleansing and photoprotection, and they were advised to avoid sun exposure.

### Efficacy assessments

Efficacy assessments included IGA grading and inflammatory acne lesion counting (including nodules, papules, and pustules). IGA grading was performed at each patient visit, and acne lesions were counted at weeks 4, 6, and 12. The primary endpoint was defined as an improvement of at least two grades on the IGA scale from baseline to week 12. Efficacy assessments were performed in the same examining room and under the same lighting conditions.

Secondary endpoints included the percentage of patients with a reduction of at least one grade on the IGA scale at weeks 6 and 12, the percentage of patients with a reduction to grade 0 or 1 on the IGA scale at weeks 6 and 12, the percentage of patients with a decrease of at least 40% in inflammatory lesion counts at weeks 6 and 12 (all compared to baseline). The acne impact on patients' quality of life was assessed with the Cardiff Acne Disability Index (CADI)<sup>11</sup> at baseline and weeks 6 and 12. Question 5 of the questionnaire was amended and split into two related questions to accommodate the split-face design of the study: "Please indicate how bad you think your acne is now on the right side of your face" (question 5a) and "Please indicate how bad you think your acne is now on the left side of your face" (question 5b). Total CADI scores and changes were compared between the treated and control hemiface of each patient. Standardized photographs of the face were taken by a professional photographer at baseline, week 6, and week 12.

### Safety assessments

Safety and tolerability were assessed through physical exam, vital signs, laboratory evaluations, and patients' reporting of adverse events. A physical exam and laboratory evaluations (complete blood count, biochemistry, and urine) were performed at baseline, week 6, and week 12. Adverse events, device incidents, and device deficiencies were recorded at each visit.

### Statistical analysis

All statistical analyses were performed by a third party using SAS<sup>®</sup> Release 9.2 software (SAS INSTITUTE Inc., Cary, NC, USA). Sample size estimation was determined according to the efficacy assessment primary endpoint. Assuming a clinical success rate of 40% for the treated group and 15% for the control, a two-sided Fisher exact test with a type I error rate (alpha level) of 5% and a type II error rate of 10% (power of 90%) required a minimum of 72 patients to demonstrate efficacy. The intent-to-treat population was used to analyze all primary and secondary endpoints. If either hemiface was missing a value, the most recent non-missing value was carried forward. There were two IGA grades collected per week for the 6 weeks of treatment, and the latter or second evaluation of the week in question was used for these analyses (Last Observation Carried Forward). The exact McNemar's test was used to analyze efficacy endpoints.  $P \leq 0.05$  was considered statistically significant.

## Results

### Efficacy assessments

A total of 104 patients with moderate to severe acne were eligible for inclusion in the study and screened for enrolment. Of these, 98 (94%) were randomized and 90 (92%) underwent at least one treatment session. Five patients decided to withdraw their consent before receiving a first treatment, and three patients were not treated as the study enrollment period was ended (Fig. 1). The mean age of treated patients was 21 years old, and the majority were female (75.6%,  $n = 68$ ). At baseline, 54 patients (60%) exhibited moderate acne (IGA grade 3) and 36 (40%) exhibited severe acne (IGA grade 4) (Table 2). The mean number of treatments carried out per patient was 11.4 (range 1–12). Eighty-five patients (86.7%) completed 6 weeks of treatment, and 79 (80.6%) completed the 12-week study. The most common reasons for treatment discontinuation were patient's wish ( $n = 8$ ) and relocation ( $n = 3$ ).

At week 12, 46 (51.7%) treated hemifaces achieved the primary endpoint of a reduction of at least two grades in the IGA scale, compared to 16 (18.0%) of the control hemifaces ( $P < 0.0001$ ) (Table 3). This reduction of at least two grades in the IGA scale was evident from week 4 in some patients, while the number of patients that achieved this response continued to increase up to week 12 (Fig. 2).

For the treated hemiface group, 18% of patients achieved an IGA grade of 0 or 1 (acne: clear or almost clear) versus 6.7% for the control at week 6 ( $P = 0.0213$ ), and this response was significant at week 12 for the treated hemifaces (32.6% vs. 11.2% in control hemifaces,  $P < 0.0001$ ) (Table 3). The percentage of

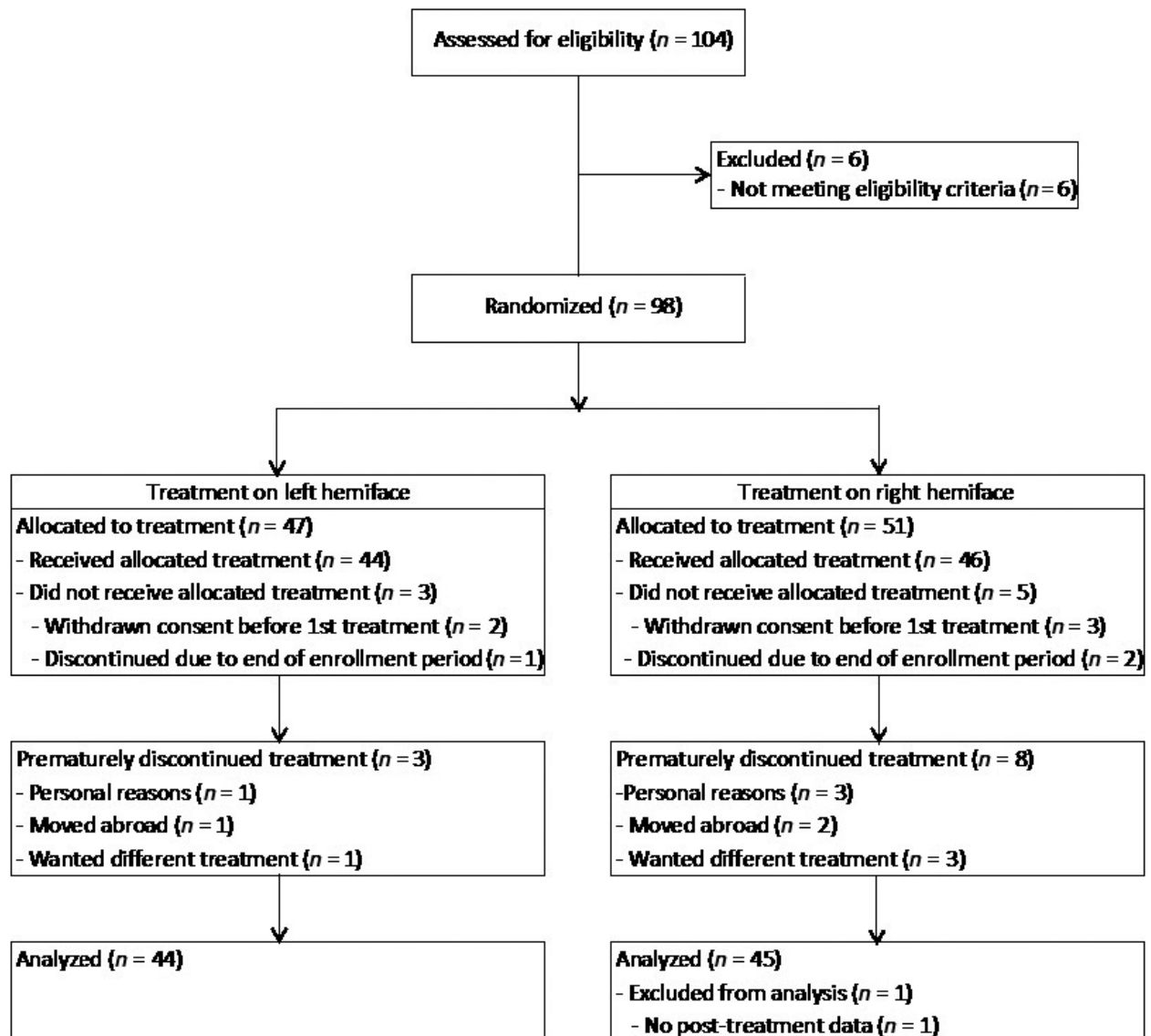


Figure 1 Patient diagram flow

treated hemifaces that attained a reduction of at least one IGA grade at week 6 was 79.8%, compared with 48.9% for the untreated hemifaces ( $P < 0.0001$ ). This response was sustained at week 12 follow-up (88.8% treated vs. 69.7% control;  $P < 0.0001$ ) (Table 3).

For acne lesion counts, clinical response was defined as a reduction of at least 40% of inflammatory acne lesions from baseline to weeks 6 and 12. At week 6, 64.4% of the treated group achieved this endpoint, compared with 31.0% of the controls ( $P < 0.0001$ ). This effect increased at week 12 (81.6% treated vs. 46.0% control [ $P < 0.0001$ ]) (Fig. 3).

For patients with severe acne, 61.1% achieved an IGA reduction of at least two grades, while 45.3% of the patients with moderate acne (baseline IGA 3) achieved

this. Both subgroups responded to study treatment by having a reduction of at least 40% in inflammatory lesion counts at week 12 (80.8% vs. 82.9%).

Clinical response is shown in photographs of the treated hemiface compared to the untreated/control hemiface (Figs. 4 and 5).

The comparison of CADI scores indicated a decrease of 40% in the treated hemifaces at weeks 6 and 12, whereas an increase in CADI scores of 20% was observed for the untreated/control group at the same time points.

#### Safety assessments

The study treatment was safe and well tolerated. Of the 90 patients who underwent treatment, 18 (20.0%)

**Table 2** Baseline characteristics of randomized patients who underwent at least one treatment session ( $n = 90$ ), Greece

Characteristic	
Age, years	
Mean (SD)	21.0 (4.1)
Median	21.0
Range	16–30
Ethnicity, $n$ (%)	
Caucasian	88 (97.8)
Other	2 (2.2)
Gender, $n$ (%)	
Female	68 (75.6)
Male	22 (24.4)
Baseline IGA grade, $n$ (%)	
Treated hemiface	
3	54 (60)
4	36 (40)
Control hemiface	
3	54 (60)
4	36 (40)
Inflammatory acne lesion counts	
Treated hemiface	
Mean (SD)	23 (13.8)
Median	19
Range	8–74
Control hemiface	
Mean (SD)	23.3 (15.4)
Median	16
Range	9–82

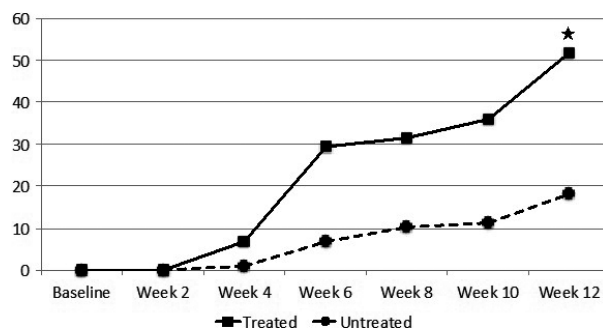
Papules, pustules, and nodules are included in the inflammatory acne lesion count.  
IGA, investigator’s global assessment.

**Table 3** Efficacy assessment results in patients with treated acne in the split-face study, Greece

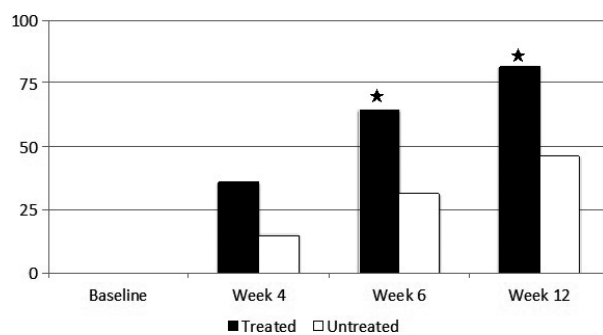
Evaluation	Time point	Treated hemiface, $n$ (%)	Control hemiface, $n$ (%)	$P$ value
$\geq 2$ grades reduction in IGA scale <sup>a</sup>	Week 12	46 (51.7)	16 (18)	<0.0001
IGA grade reduction to 0 or 1	Week 6	16 (18)	6 (6.7)	0.0213
	Week 12	29 (32.6)	10 (11.2)	<0.0001
$\geq 1$ grade reduction in IGA scale	Week 6	71 (79.8)	44 (48.9)	<0.0001
	Week 12	79 (88.8)	62 (69.7)	<0.0001
Inflammatory acne lesion counts				
$\geq 40\%$ reduction	Week 6	57 (64.4)	28 (31)	<0.0001
	Week 12	73 (81.6)	41 (46)	<0.0001

IGA, investigator’s global assessment.  
<sup>a</sup>Primary endpoint.

reported a total of 34 adverse events of which 16 were considered as treatment-related emergent adverse events (TEAEs, defined as possibly, likely, or definitely caused by the treatment). Of these, all were transient and all except one were rated mild or moderate in intensity



**Figure 2** Percentage of hemifaces (treated vs. untreated/control) with a reduction of at least two grades in investigator’s global assessment scale over time. \*Statistically significant result  $P < 0.0001$



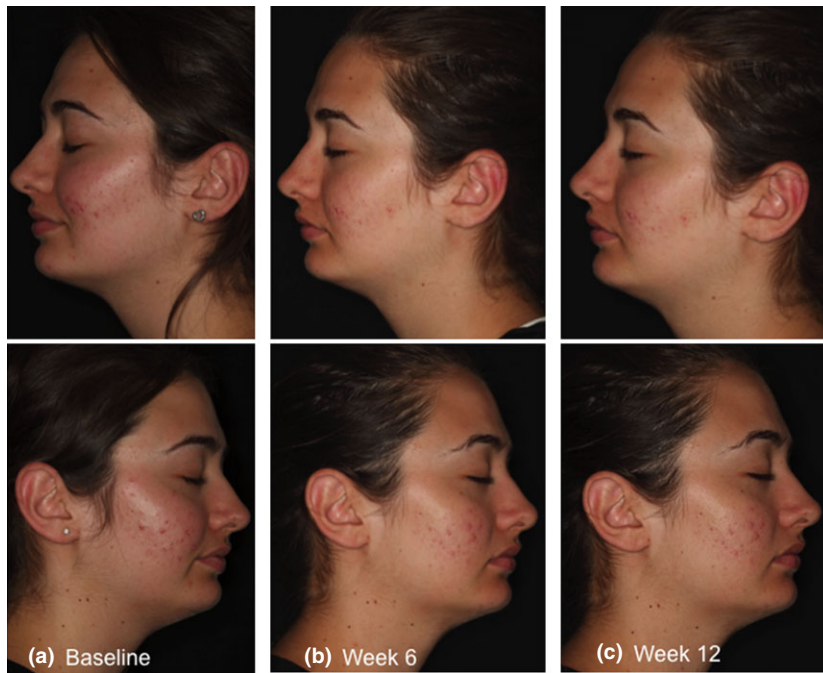**Figure 3** Percentage of hemifaces (treated vs. untreated/control) with at least 40% reduction in inflammatory acne lesion counts over time. \*Statistically significant result  $P < 0.0001$

(Table 4). The most frequent TEAEs ( $\geq 5\%$ ) were hair color lightening (6.7%), erythema (5.6%), and skin hyperpigmentation (5.6%). The hair color changes observed were eyebrow lightening due to the contact application of the gel with the patient’s eyebrow. The single severe TEAE was a case of pruritus, which occurred on a treated hemiface and resolved within 5 minutes without any intervention. No patient discontinued the study because of any TEAE, and no TEAE was reported on any untreated/control hemiface.

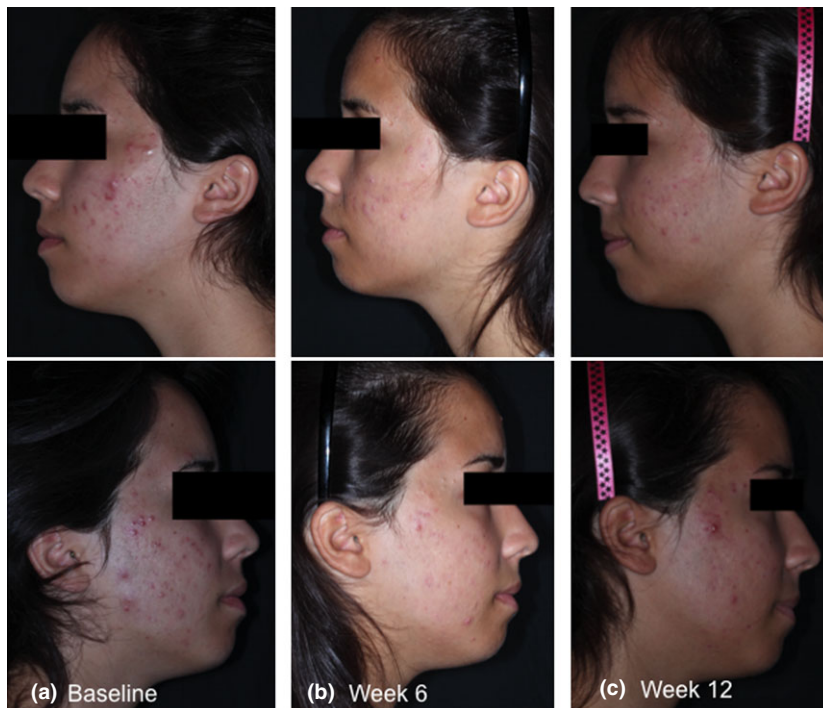Pain was assessed at each visit using the Visual Analog Scale (VAS) from 0 to 10 (0 = no pain; 10 = worst pain ever). The VAS mean pain score was 1.7 at baseline, and the overall VAS pain score decreased over the 6-week treatment period, reaching a minimum of 0.2 at the end of the follow-up period (week 12).

**Discussion**

Acne has recently been characterized as a chronic disease, and experts agree that it should be managed as such.<sup>12</sup> The emergence of worldwide antibiotic-resistant *P. acnes*



**Figure 4** Clinical response in the treated hemiface (upper panel) compared to the untreated/control hemiface (lower panel) at baseline (a) week 6 (b) and week 12 (c)



**Figure 5** Clinical response in the treated hemiface (upper panel) compared to the untreated/control hemiface (lower panel) at baseline (a) week 6 (b) and week 12 (c)

bacteria<sup>13</sup> and adverse effects associated with isotretinoin,<sup>14</sup> have further fueled the need for alternatives in the management of moderate and severe acne.<sup>12</sup> Although light therapies have gained increasing interest over the last years as acne treatments, there is still scarce evidence-based data regarding their efficacy, not permitting them

to be strongly recommended for moderate or severe inflammatory acne according to official guidelines and consensus recommendations.<sup>2,7</sup> This is due to the fact that there are not enough randomized controlled studies on light therapy for acne.<sup>2,4,7,15</sup> There are only four published controlled studies of blue light therapy for acne: (i)

**Table 4** TEAEs in treated patients ( $n = 90$ )

Adverse event	Mild	Moderate	Severe
Patients with at least 1 TEAE, $n$ (%)	10 (11.1)	5 (5.6)	1 (1.1)
Application site pain	3 (3.3)	0	0
Face edema	1 (1.1)	0	0
Infections			
Oral herpes	0	1 (1.1)	0
Cutaneous adverse events			
Erythema	4 (4.4)	1 (1.1)	0
Pruritus	1 (1.1)	0	1 (1.1)
Skin hyperpigmentation	5 (5.6)	0	0
Hair color lightening	3 (3.3)	3 (3.3)	0

TEAE, treatment emergent adverse event (defined as those possibly, likely or definitely causally related to treatment); for each patient, only the most severe event is summarized.

the randomized controlled (split-face) study of Tzung *et al.* in 31 patients showed efficacy compared to no treatment;<sup>16</sup> (ii) the controlled (split-face) study of Elman *et al.*, in 23 patients reported significant (59–67%) reduction of inflammatory lesions compared to no treatment;<sup>17</sup> (iii) the randomized, controlled study of Ash *et al.*, in 41 patients with mild to moderate acne reported significant reduction of mean lesion counts by 50.02% in patients treated with a hand-held LED device (414 nm);<sup>18</sup> while (iv) Papageorgiou *et al.* randomized 107 patients into four groups (blue light, red–blue light, benzoyl peroxide, and cool white light [portable light sources]), and reported that for inflammatory acne lesions the blue–red light was superior to benzoyl peroxide, while there was no significant difference compared to blue light at week 12.<sup>19</sup> Gold *et al.* compared blue light to topical clindamycin,<sup>20</sup> and Goldman and Boyce compared two sessions of blue light to blue light PDT in 22 patients,<sup>21</sup> but results in these studies were not statistically analyzed.

In our multicenter, randomized, split-face study, we showed that the use of chromophore-assisted blue light multi-LED phototherapy twice weekly for 6 weeks was efficacious, resulting in a reduction of at least two grades in the IGA scale in a statistically significant number of treated hemifaces of patients at 12 weeks (51.7% compared to 18.0% of the untreated hemifaces,  $P < 0.0001$ ). When compared to untreated hemifaces, there was a statistically significant reduction of at least 40% in inflammatory acne lesion counts in 64.4% of treated hemifaces at the end of the 6-week treatment period ( $P < 0.0001$ ). This was maintained and further increased at week 12 (81.6% treated vs. 46.0% in control [ $P < 0.0001$ ]). Interestingly, a high proportion of patients with severe acne (baseline IGA 4) benefited from this treatment. Study treatment was safe and very well tolerated, as previously reported, for blue light therapy.<sup>20,22</sup>

Limitations of our study include the absence of an established active acne topical agent as a control group; however, the use of the untreated half-part of the face as a control allowed for conclusions to be drawn compared to no treatment. The importance of a control or the no-treatment arm for acne is important as there is a considerable proportion of self-remission in acne; in our study, 48.9% of the untreated hemifaces showed a reduction of at least one IGA grade at week 6, but importantly there was a statistically significant higher percentage of treated hemifaces (79.8%) that showed this response with treatment. An alternative intriguing explanation of the high response rate in the untreated hemifaces may be justified by possible residual anti-inflammatory effects of phototherapy in the adjacent untreated half-part of the face. Another limitation of our study is that the majority of included patients were female, so our results mostly apply to this population.

Optical light treatments in acne mediate their effects via photothermal heating of sebaceous glands and photochemical inactivation of *P. acnes*, which produces coproporphyrins and protoporphyrins. Moreover, a photoimmunological reaction might contribute to acne improvement.<sup>15</sup> The activation of *P. acnes*-produced fluoro-chrome-like porphyrins with visible light results in decreased bacterial density, while blue light activation of porphyrins causes bacterial membrane damage and triggers apoptosis by producing cytotoxic reactive oxygen species.<sup>23–26</sup> Blue light may also exhibit anti-inflammatory effects,<sup>27–29</sup> and treatment with blue and red light results in significantly decreased sebum output and sebaceous gland size.<sup>29</sup> Protoporphyrin IX has its largest absorption peak in the blue region at 410 nm (Soret band: 360–400 nm), with four smaller absorption peaks at 505, 540, 580, and 630 nm. Ashkenazi *et al.* demonstrated *in vitro* that through endogenous porphyrin production, particularly coproporphyrin III, *P. acnes* can be temporarily eradicated via an endogenous photodynamic reaction with blue light illumination.<sup>23</sup> The topical gel used in our study contains chromophores that are not required to be absorbed by the skin to exert their actions. When chromophores are excited with applied wavelengths, they release photons with wavelengths that still lie within the visible spectrum, from blue to orange (400–610 nm); it is the diffraction of light via the chromophore gel that may result in better epidermal and dermal absorption of light and enhance its actions.

Our study demonstrated that chromophore-assisted blue light phototherapy twice weekly for 6 weeks was efficacious, safe, and well tolerated, with sustained clinical response at 12 weeks, providing a further treatment option for patients with moderate and severe inflammatory acne of the face.

## Acknowledgments

We thank all study participants, investigational clinical sites staff, and collaborators who contributed to this study. KLOX Technologies Inc. sponsored the clinical trial.

## References

- Tan JKL, Bhate K. A global perspective on the epidemiology of acne. *Br J Dermatol* 2015; 172(Suppl. 1): 3–12.
- Thiboutot D, Gollnick H, Bettoli V, et al. New insights into the management of acne: an update from the Global Alliance to improve outcomes in acne group. *J Am Acad Dermatol* 2009; 60: s1–s50.
- Katsambas A, Dessinioti C. New and emerging treatments in dermatology: acne. *Dermatol Ther* 2008; 21: 86–95.
- Hamilton FL, Car J, Lyons C, et al. Laser and other light therapies for the treatment of acne vulgaris: systematic review. *Br J Dermatol* 2009; 160: 1273–1285.
- Katsambas AD, Dessinioti C. Hormonal therapy for acne: why not as first-line therapy? Facts and controversies *Clin Dermatol* 2010; 28: 17–23.
- Sakamoto FH, Lopes JD. Rox Anderson R. Photodynamic therapy for acne vulgaris: a critical review from basics to clinical practice. Part I. Acne vulgaris. *J Am Acad Dermatol* 2010; 63: 183–193.
- Nast A, Dreno B, Bettoli V, et al. European evidence-based (S3) guidelines for the treatment of acne. *J Eur Acad Dermatol Venereol* 2012; 26(Suppl. 1): 1–29.
- Dessinioti C, Katsambas A, Masouri S, et al. Short-contact low-dose methyl aminolaevulinate-photodynamic therapy (MAL-PDT) for the treatment of acne vulgaris: a hospital-based case series. Poster P112. 12th EADV Spring Symposium, Valencia, Spain, March 2015.
- Wiegell SR, Wulf HC. Photodynamic therapy of acne vulgaris using 5-aminolevulinic acid versus methyl aminolevulinate. *J Am Acad Dermatol* 2006; 54: 647–651.
- U.S. Department of Health and Human Services Food and Drug Administration Center for Drug Evaluation and Research (CDER). Guidance for industry. Acne vulgaris: developing drugs for treatment. 2005. <http://www.fda.gov/downloads/Drugs/GuidanceComplianceRegulatoryInformation/Guidances/UCM071292.pdf> [Accessed September 11, 2014].
- Motley RJ, Finlay AY. Practical use of a disability index in the routine management of acne. *Clin Exp Dermatol* 1992; 17: 1–3.
- Dreno B. The changing faces of acne. *Br J Dermatol* 2015; 172(Suppl. 1): 1–2.
- Ross JI, Snelling AM, Carnegie E, et al. Antibiotic-resistant acne: lessons from Europe. *Br J Dermatol* 2003; 148: 467–478.
- Zouboulis CC, Bettoli V. Management of severe acne. *Br J Dermatol* 2015; 172: 27–36.
- Haedersdal M, Togsverd-Bo K, Wulf HC. Evidence-based review of lasers, light sources and photodynamic therapy in the treatment of acne vulgaris. *J Eur Acad Dermatol Venereol* 2008; 22: 267–278.
- Tzung TY, Wu KH, Huang ML. Blue light phototherapy in the treatment of acne. *Photodermatol Photoimmunol Photomed* 2004; 20: 266–269.
- Elman M, Slatkine M, Harth Y. The effective treatment of acne vulgaris by a high-intensity, narrow band 405–420 nm light source. *J Cosmet Laser Ther* 2003; 5: 111–117.
- Ash C, Harrison A, Drew S, et al. A randomized controlled study for the treatment of acne vulgaris using high-intensity 414 nm solid state diode arrays. *J Cosmet Laser Ther* 2015; 17: 170–176.
- Papageorgiou P, Katsambas A, Chu A. Phototherapy with blue (415 nm) and red (660 nm) light in the treatment of acne vulgaris. *Br J Dermatol* 2000; 142: 973–978.
- Gold MH, Rao J, Goldman MP, et al. A multicenter clinical evaluation of the treatment of mild to moderate inflammatory acne vulgaris of the face with visible blue light in comparison to topical 1% clindamycin antibiotic solution. *J Drugs Dermatol* 2005; 4: 64–70.
- Goldman MP, Boyce SM. A single-center study of aminolevulinic acid and 417 nm photodynamic therapy in the treatment of moderate to severe acne vulgaris. *J Drugs Dermatol* 2003; 2: 393–396.
- Liu LH, Fan X, An YX, et al. Randomized trial of three phototherapy methods for the treatment of acne vulgaris in Chinese patients. *Photodermatol Photoimmunol Photomed* 2014; 30: 246–253.
- Ashkenazi H, Malik Z, Harth Y, et al. Eradication of *Propionibacterium acnes* by its endogenous porphyrins after illumination with high intensity blue light. *FEMS Immunol Med Microbiol* 2003; 35: 17–24.
- Santos MAV, Belo VG, Santos G. Effectiveness of photodynamic therapy with topical 5-aminolevulinic acid and intense pulsed light versus intense pulsed light alone in the treatment of acne vulgaris: comparative study. *Dermatol Surg* 2005; 31: 910–915.
- Maclean M, MacGregor SJ, Anderson JG, et al. The role of oxygen in the visible-light inactivation of *Staphylococcus aureus*. *J Photochem Photobiol, B* 2008; 92: 180–184.
- Momen S, Al-Niaimi F. Acne vulgaris and light-based therapies. *J Cosmet Laser Ther* 2015; 17: 122–128.
- Shnitkind E, Yaping E, Geen S, et al. Anti-inflammatory properties of narrow-band blue light. *J Drugs Dermatol* 2006; 5: 605–610.
- Tremblay JF, Sire DJ, Lowe NJ, et al. Light-emitting diode 415 nm in the treatment of inflammatory acne: an open-label, multicentric, pilot investigation. *J Cosmet Laser Ther* 2006; 8: 31–33.
- Kwon HH, Lee JB, Yoon JY, et al. The clinical and histological effect of home-use, combination blue-red LED phototherapy for mild-to-moderate acne vulgaris in Korean patients: a double-blind, randomized controlled trial. *Br J Dermatol* 2013; 168: 1088–1094.